

## Promotion of cutaneous wound healing by famotidine in Wistar rats

K.S. Rao, P.A. Patil & P.R. Malur

*Department of Pharmacology & Pharmacotherapeutics, J.N. Medical College, Belgaum, India*

Received June 23, 2006

***Background & objectives:*** Drugs like famotidine, omeprazole and sucralfate which have been reported to promote the healing of gastric ulcers, may have the same effect on cutaneous wounds. Due to paucity of information in this regard, the present study was planned to investigate the effect of these drugs on resutured incision, excision and dead space wounds in Wistar rats.

***Methods:*** Resutured incision, excision and dead space wounds were inflicted under light ether anaesthesia aseptically. Control animals received vehicle and other groups received famotidine, omeprazole and sucralfate orally for a period of 10 days in the incision and dead space wounds, whereas in excision wounds till complete closure. On the 11<sup>th</sup> day after estimating breaking strength of the resutured incision wounds, animals were sacrificed and granulation tissue removed from dead space wounds to estimate the breaking strength and hydroxyproline content. Quantification of granulation tissue and histological studies were also carried out. Wound closure rate, epithelization time and scar features were studied in the excision wound models from the day of famotidine till complete closure of the wound.

***Results:*** Only famotidine significantly promoted the healing process in all the three wound models studied. Histopathological studies revealed increased collagen content and granulation tissue in famotidine treated group compared to control.

***Interpretation & conclusion:*** In all the three wound models studied famotidine promoted wound healing whereas omeprazole and sucralfate did not do so. The pro healing effect of famotidine needs to be explored clinically.

**Key words** Famotidine - omeprazole - sucralfate - wound healing

Peptic ulcer, a common clinical entity is treated by a variety of antisecretory drugs. Apart from antibiotics to eradicate *Helicobacter pylori* infection other drugs like famotidine, omeprazole and sucralfate act by suppressing acid secretion to promote the healing process. However, sucralfate is known to promote healing by inhibiting peptic hydrolysis of mucosal proteins and by stimulating local release of prostaglandins. Recent studies indicate that in addition to acid suppression famotidine promotes healing by enhancing angiogenesis<sup>1</sup> while omeprazole enhances wound contraction<sup>2</sup>, thereby hastens the healing. Sucralfate has been reported to increase the activity of epidermal growth factor<sup>3</sup> which enhances the cell proliferation and thus contributes in healing.

Though sucralfate has been reported to promote healing of burn wounds<sup>4</sup>, there is scanty information regarding the effect of famotidine, and omeprazole on healing of cutaneous wounds.

Since the healing process in all the tissues is similar, the present study was planned to investigate the effect of famotidine, omeprazole and sucralfate in their therapeutic equivalent concentrations on different models of cutaneous wounds *viz.*, resutured incision, excision and dead space wounds in male Wistar rats.

### Material & Methods

Healthy, male, adult, Wistar rats weighing 150-250 g (procured from Central Animal House of the Institute) were housed individually and maintained on standard pellet diet with water *ad libitum* in the departmental laboratory for a week to acclimatize. The study protocol was approved by the institutional animal ethics committee and ethical norms were strictly followed during experimental procedures. After careful depilation (without injuring the skin) at the wounding site the animals were starved overnight prior to the day of experimentation and divided into control and treatment groups (n=6 in

each) for each wound model. Famotidine (Cadilla Health Care Ltd., Ahmedabad), omeprazole (Dr Reddy's Laboratories, Hyderabad), and sucralfate (procured from D.K. Enterprises, Mumbai and manufactured by Zydus Alidac Pharmaceuticals, Ahmedabad) were obtained as generous gifts from the respective pharmaceutical companies. The above mentioned drugs were administered orally in therapeutic equivalent doses (per kg body weight of rat) as calculated with the help of conversion table devised by Paget and Barnes<sup>5</sup>. The doses of famotidine (3.6 mg/kg), omeprazole (3.6 mg/kg) and sucralfate (360 mg/kg) were suspended in 2 per cent gum acacia and were administered orally once daily (0900) in the volume of 5 ml/kg, while control groups received equal volume of vehicle. The duration of treatment was 10 days for animals inflicted with incision and dead space wounds, while it was continued in animals bearing excision wounds till the complete closure of the wounds.

#### Wound models:

(i) Resutured incision wounds were inflicted with two 6 cm long paravertebral parallel incisions under light ether anaesthesia as described earlier<sup>6</sup>. Sutures were removed on 8<sup>th</sup> day and breaking strength was measured on 11<sup>th</sup> day post wounding by continuous water flow technique<sup>7</sup>. Three readings were taken on each wound and the mean of six such readings in each animal was used for statistical analysis. Subsequently animals were sacrificed by overdose of anaesthesia.

(ii) Excision wounds were made as described by Morton and Malone<sup>8</sup> by excising the full thickness circular skin (approximately 500 mm<sup>2</sup>) from the nape of the neck under ether anaesthesia. Wound closure rate was assessed by tracing the wound on polythene paper on wounding day, followed by 4<sup>th</sup>, 8<sup>th</sup>, 12<sup>th</sup>, 16<sup>th</sup> day and subsequently on every alternate day/daily till complete closure. Falling of the scab without any raw area indicated time for complete epithelization and the same was noted. Similarly, scars were traced

on complete epithelization to assess wound contraction by noting scar size and shape. Round/oval, large scars indicated poor contraction while stellate shaped or linear scars indicated enhanced wound contraction.

(iii) Dead space wounds were inflicted by implanting sterile cotton pellets (10 mg) and cylindrical grass piths (25 mm x 3mm) subcutaneously in the groin and axilla randomly by the technique of D'Arcy *et al*<sup>9</sup>. The granulation tissues were removed on 11<sup>th</sup> day post wounding. All the granulation tissues were dissected out after sacrificing the animal and were dried at 60°C overnight to record the constant dry weight, expressed as mg/100g body weight<sup>10</sup>. One of the granulation tissues over the grass piths was opened and trimmed to a rectangular piece for estimation of breaking strength and subsequent estimation of hydroxyproline content colorimetrically<sup>11</sup>. The other granulation tissue grown on the grass pith was preserved in 10 per cent formalin for histological studies. All the surgical procedures were carried out aseptically and none of the animals were treated with local or systemic antimicrobial agents.

*Statistical analysis:* The data were analyzed by ANOVA followed by Dunnet's test,  $P < 0.05$  was considered significant.

## Results

*Resutured incision wounds:* Famotidine significantly ( $P < 0.01$ ) increased wound breaking strength compared to that of control. However, omeprazole and sucralfate did not show any significant effect on breaking strength (Table I).

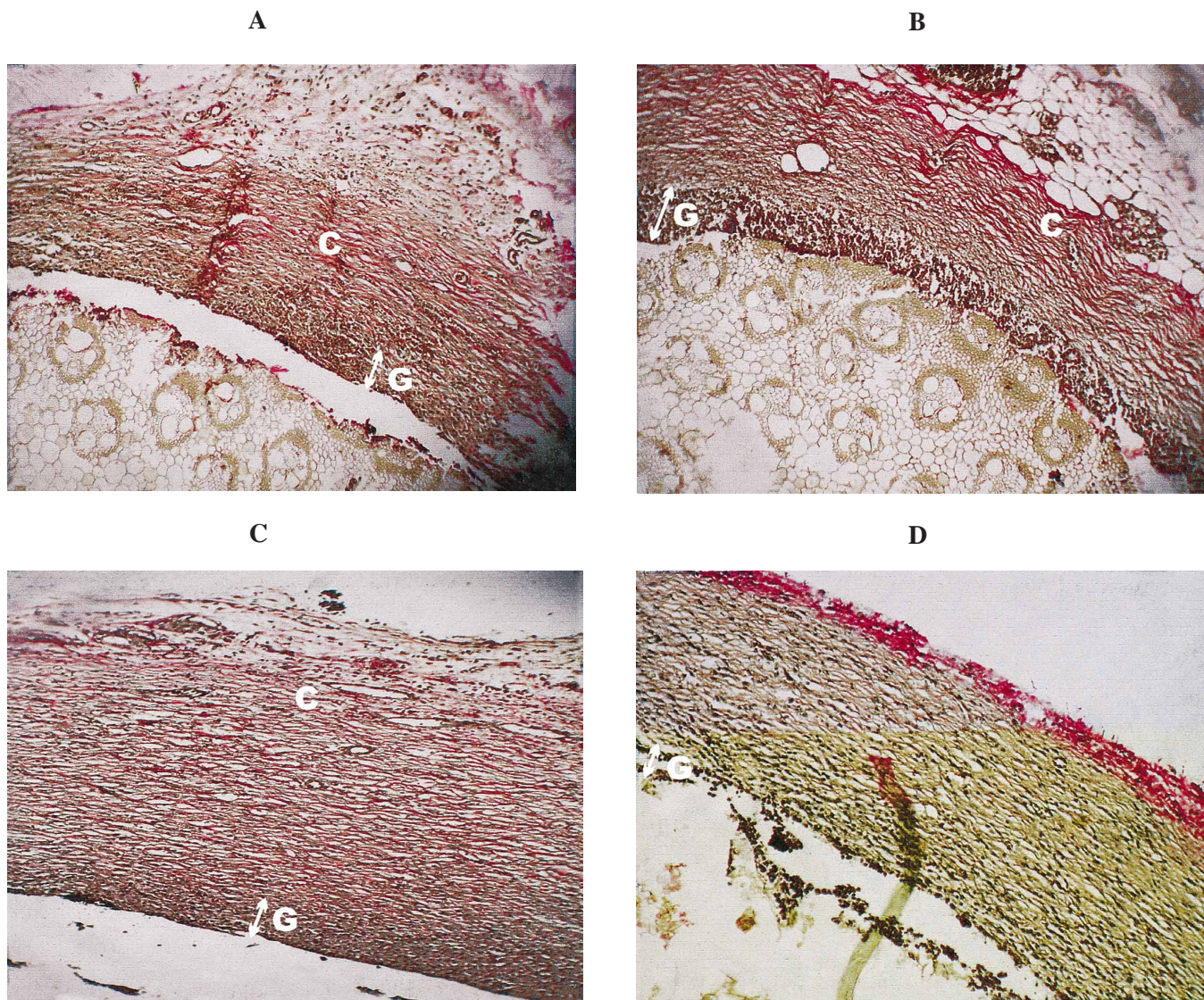
*Dead space wounds:* Famotidine significantly ( $P < 0.05$ ) increased breaking strength of granulation tissue similar to its effects in resutured incision wounds. Breaking strength of the granulation tissue in the omeprazole and sucralfate treated group did not significantly differ from that of control (Table I). Cotton pellet granuloma weight was increased significantly ( $P < 0.01$ ) in the famotidine treated group ( $47.74 \pm 2.29$  mg%) as compared to that of control ( $32.28 \pm 1.01$  mg%), while granuloma dry weight in omeprazole treated group ( $29.92 \pm 1.02$  mg%) and in sucralfate treated animals ( $35.36 \pm 1.80$  mg%) did not significantly differ from that of control (Table I).

Hydroxyproline content was significantly ( $P < 0.01$ ) increased in famotidine treated animals in comparison to that of control.

**Table I.** Effect of various healing agents on resutured incision and dead space wounds

Group (n=6)	Dose (mg/kg) orally	Resutured incision wound breaking strength (g)	Granulation tissue		
			Breaking strength (g)	Dry weight (mg % of body weight)	Hydroxyproline ( $\mu$ g/900 mg of wet granulation tissue)
Control	2% Gum acacia (5 ml/kg)	187.1 $\pm$ 8.67	203.3 $\pm$ 12.29	32. 28 $\pm$ 1.01	5.917 $\pm$ 0. 41
Famotidine		282 $\pm$ 8.3**	246 7 $\pm$ 10.22*	47.74 $\pm$ 2.29**	10.38 $\pm$ 0.43**
Omeprazole		202.8 $\pm$ 8.4	201.7 $\pm$ 8.33	29.92 $\pm$ 1.03	5.458 $\pm$ 0.40
Sucralfate		209.5 $\pm$ 6.19	233.3 $\pm$ 17.26	35.36 $\pm$ 1.8	6.833 $\pm$ 0.26

Values are mean  $\pm$  SEM  
 $P^* < 0.01$ ;  $^{**} < 0.01$  compared to control



**Fig.** Photomicrographs showing marked increase in granulation tissue and collagen content in famotidine treated group (Van Giesons stain, 10x). **A.** control; **B.** famotidine; **C.** sucralfate; **D.** omeprazole. G, granulation tissue; C, collagen.

Histopathological studies revealed increased collagen content and granulation tissue in the famotidine treated group in contrast to control and other treatment groups. However, there was a large amount of fibrous tissue in the sucralfate treated group (Fig.).

*Excision wounds:* The rate of wound closure in famotidine treated animals was significantly ( $P < 0.01$ ) more on 4<sup>th</sup>, 12<sup>th</sup>, 16<sup>th</sup>, day as compared to

that of control. However, there was no significant change in rate of wound closure in omeprazole and sucralfate treated animals as compared to control animals. The time for epithelization was  $19.83 \pm 0.70$  days in control group, while it was significantly ( $P < 0.01$ ) decreased in the famotidine group with a mean value of  $16.67 \pm 0.42$  days (Table II). Omeprazole and sucralfate treated groups showed insignificant change as compared to control.

The stellate shaped smaller scars observed in the famotidine treated group indicated enhanced wound contraction, while scars with large area (Table II) in the omeprazole and sucralfate groups were comparable to those in control denoting poor wound contraction.

**Discussion**

The results of the present study clearly indicated that famotidine enhanced healing of all the three types of cutaneous wounds, while omeprazole failed to do so. However, it is not clear as to why famotidine failed to promote healing of excision wounds from day 5 to day 8 of the study.

Famotidine has been reported to increase angiogenesis<sup>1</sup> which is essential for cell proliferation. The results of the present study regarding famotidine could be attributed to its systemic absorption and promotion of angiogenesis at the wound site, as denoted by enhanced granulation tissue and increased collagen content in histological studies.

Omeprazole which has been reported to enhance wound contraction<sup>2</sup> in gastric ulcers, has failed to do so in cutaneous wounds despite being absorbed systemically. This could probably be due to its short half life, extensive metabolism in the liver, and also probably due to its ineffective concentration at the wound site.

Sucralfate has failed to influence the healing of all the three types of cutaneous wounds in the present study though it is reported to promote the healing of gastric ulcers. Failure of sucralfate to promote the wound healing can be explained on the basis of its poor systemic absorption<sup>12</sup>. Sucralfate has been reported to promote the healing of burn wounds<sup>4</sup> when applied locally possibly due to its local effect on epidermal growth factor<sup>3</sup> and prostaglandins. The discrepancy may be due to the route of administration rather than the wound model and the pro healing activity of sucralfate in earlier reports could be due to its local effects on prostaglandins.

In conclusion, famotidine promoted wound healing in all the three cutaneous wound models. This prohealing effect of famotidine needs to be investigated further.

**Table II.** Effect of various healing agents on excision wounds

Group (n=6) in each	Dose (mg/kg) orally	Wound closure (% of original area) in mm <sup>2</sup> on day (Mean ± SEM)						
		4	8	12	16	18	Days for complete closure	Scar area (mm <sup>2</sup> )
Control	Gum acacia 2% (5 ml/kg)	19.07±	53.57±	81.28±	88.88±	94.97±	19.83±	41.83±
		1.76	3.04	2.96	1.63	2.04	0.70	1.537
Famotidine	3.6	34.22±	56.42±	94.58±	99.43±	100±	16.67±	34.17±
		1.07**	2.67	1.15**	0.37**	0.00*	0.42**	0.70**
Omeprazole	3.6	21.12±	54.87±	86.43±	90.83±	95.88±	19.50±	40.33±
		0.68	1.73	1.83	1.38	0.96	0.22	0.95
Sucralfate	360	18.87±	49.82±	80.40±	87.92±	94.27±	20±	41±
		0.86	1.49	1.80	2.46	1.75	0.52	1.75

P\* < 0.05; \*\* < 0.01 compared to controls

### Acknowledgment

The authors thank the Principal, J.N. Medical College, Belgaum, for providing the facilities to conduct the study, Shri M.D. Mallapur, Biostatistician for his help. Shriyuts M.D. Kankanwadi, A.V. Karvekar, M.R. Ambewadi and Smt. Madhumati for assistance. Authors acknowledge Cadilla Health Care Ltd, Ahmedabad, Dr Reddy's Laboratories, Hyderabad, D.K. Enterprises, Mumbai and Zydus Alidac Pharmaceuticals, Ahmedabad, for supplying the drug samples.

### References

1. Hnatyszyn A. Comparison of the effectiveness of antiulcer drugs and their influence on angiogenesis in healing of experimental chronic gastric ulcer. *Ann Acad Med Stetin* 1995; 41 : 183-91.
2. Tsukimi Y, Nozue C, Okabe S. Effects of leminoprazole, omeprazole and sucralfate on indomethacin induced delayed healing of kissing gastric ulcers in rats. *J Gastroenterol Hepatol* 1996; 11 : 335-40.
3. Hardman JG, Limbird LE, Goodman Gilman A, editors. *Goodman and Gilman's : the pharmacological basis of therapeutics*. 10<sup>th</sup> ed. New York: McGraw Hill; 2001.
4. Bamati A, Chowdhary SR, Mazumdar S. Topical use of sucralfate cream in second and third degree burns. *Burns* 2001; 27 : 465-9.
5. Paget GE, Barnes JM. Toxicity tests. In : Laurence DR Bacharach AL, editors. *Evaluation of drug activities: pharmacometrics*. London and New York: Academic Press; 1964 p. 134-66.
6. Hunt TK, Ehrlich HP, Gracia JA, Dunphy JE. Effects of vitamin A on reversing the inhibitory effect of cortisone on healing of open wounds in animals and man. *Ann Surg* 1969; 170 : 633-41.
7. Lee KH. Studies on the mechanism of action of salicylates. II. Retardation of wound healing by aspirin. *J Pharm Sci* 1968; 57 : 1042-3.
8. Morton JJP, Malone MH. Evaluation of vulnary activity by an open wound procedure in rats. *Arch Int Pharmacodyn* 1972; 196 : 117-26.
9. D'Arcy PF, Howard EM, Muggleton PW, Townsend SB. The anti-inflammatory action of griseofulvin in experimental animals. *J Pharm Pharmacol* 1960; 12 : 659-65.
10. Dipasquale G, Meli A. Effect of body weight changes on the formation of cotton pellet induced granuloma. *J Pharm Pharmacol* 1965; 17 : 379-82.
11. Woessner JF Jr. The determination of hydroxyproline in tissue and protein samples containing small proportions of this immino acid. *Arch Biochem* 1961; 93 : 440-7.
12. Katzung BG, editor. *Basic and clinical pharmacology*. 9th ed. New York: McGraw-Hill; 2004.

Reprint requests: Dr P.A. Patil, Professor & Head, Department of Pharmacology & Pharmacotherapeutics  
J.N. Medical College, Belgaum 590010, India  
e-mail: drpapatil@yahoo.co.in