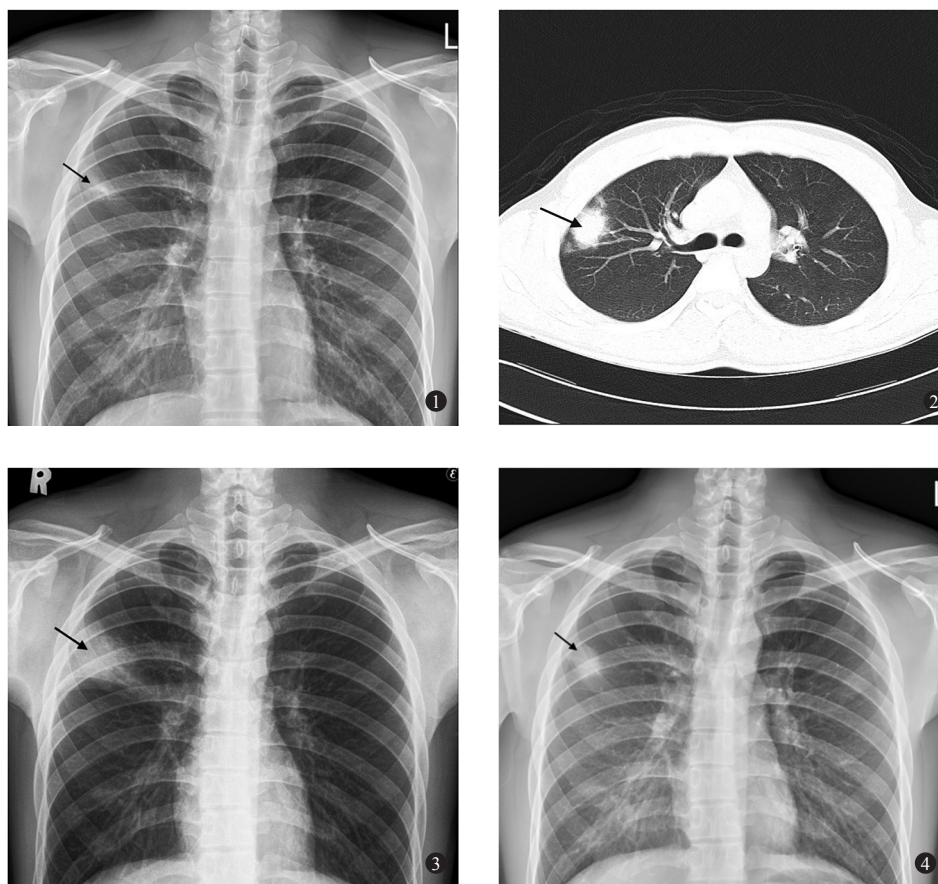


## Clinical Image

### Round pneumonia



**Fig. 1.** Posterior-anterior chest radiograph showing opacification over right upper lobe (arrow). **Fig. 2.** Non-enhanced computed tomography demonstrated a 25mm nodule in the right upper lobe (arrow). **Fig. 3.** Chest radiograph obtained 5 days later revealed a consolidation in the right upper lobe (arrow). **Fig. 4.** Repeat chest radiograph after 14 days showed regression of air-space opacification over right upper lobe (arrow).

A 25 year old non-smoker male presented to the outpatient department of the Infectious Diseases Division, Kaohsiung Armed Forces General Hospital, Taiwan, in February 2014, owing to right anterior chest wall pain for three days. A posterior-anterior chest

radiograph showed an opacification over right upper lobe (Fig. 1). Non-enhanced computed tomography demonstrated a 25mm nodule in the right upper lobe (Fig. 2). There was no lymphadenopathy. The patient was diagnosed to have round pneumonia and was

treated with amoxicillin-clavulanate for seven days. Chest radiograph obtained five days later revealed a consolidation in the right upper lobe (Fig. 3). The sputum culture yielded *Streptococcus pneumoniae*. The blood culture was unremarkable. Repeat chest radiograph after 14 days showed regression of air-space opacification over right upper lobe (Fig. 4). Round pneumonia is usually seen in the children and is uncommon in adult.

#### Acknowledgment

Authors thank Dr En-Han Huang, Department of Radiology, Kaohsiung Armed Forces General Hospital, Taiwan, for providing images.

**Kuan-Jen Su<sup>1</sup> & Jung-Chung Lin<sup>2,\*</sup>**

<sup>1</sup>Division of Infectious Diseases,  
Department of Internal Medicine,  
Kaohsiung Armed Forces General Hospital  
No.2, Zhongzheng 1<sup>st</sup> Rd., Lingya District,  
Kaohsiung City 80284 & <sup>2</sup>Division of Infectious  
Diseases & Tropical Medicine,  
Department of Internal Medicine,  
Tri-Service General Hospital,  
National Defense Medical Center,  
No. 325, Sec. 2, Chenggong Rd.,  
Neihu District, Taipei City 114,  
Taiwan (R.O.C),

*\*For correspondence:*  
jclin@mail.ndmctsgh.edu.tw