



Acute respiratory distress syndrome in scrub typhus

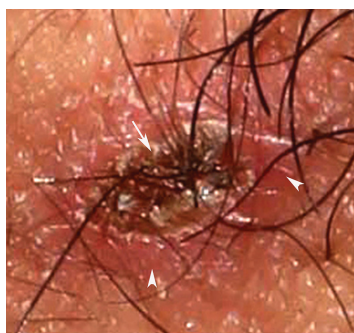

Fig. 1. Black crusted eschar surrounded by an erythematous halo in the right axilla, a pathognomonic finding in the scrub typhus (arrows head).

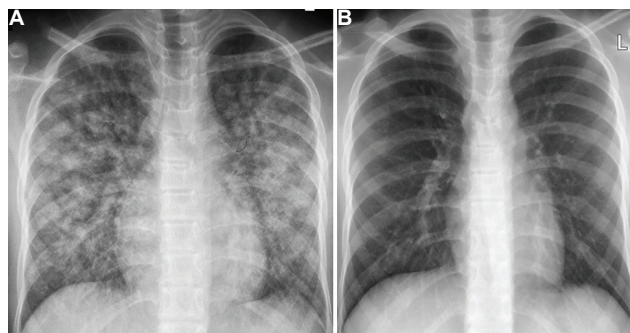


Fig. 2. (A) Chest radiograph showing bilateral lung infiltrates consistent with acute respiratory distress syndrome. (B) A normal radiograph at a three-week follow up.

A 17 yr old male child[†] admitted with fever and rapidly progressive dyspnoea for 10 days in the Emergency department of Postgraduate Institute of Medical Education & Research, Chandigarh, India, in September 2019. At admission, his oxygen saturation was 84 per cent on room air. Physical examination revealed a black crusted eschar surrounded by an erythematous halo in the right axilla (Fig. 1). Bilateral diffuse lung crackles and mild splenomegaly were present on systemic examination. The chest radiograph showed bilateral lung infiltrates (Fig. 2A). Arterial blood gas analysis revealed a PaO₂:FiO₂ ratio of 190. A nested PCR of the gene encoding the 56-kDa antigen of the Gilliam strain of *Orientia tsutsugamushi* in the blood was positive. A diagnosis of scrub typhus with acute respiratory distress syndrome (ARDS) was made.

The patient improved with antibiotics and mechanical ventilation for 72 h. A follow up radiograph at three weeks was normal (Fig. 2B).

A careful search for eschar is warranted in patients with acute undifferentiated febrile illness, as it makes a definite bedside diagnosis of scrub typhus.

Conflicts of Interest: None.

Atul Saroch & Ashok Kumar Pannu*

Department of Internal Medicine, Postgraduate
Institute of Medical Education & Research,
Chandigarh 160 012, India

**For correspondence:*
gawaribacchi@gmail.com

Received October 1, 2019

[†]The child's assent and parents' consent obtained to publish clinical information and images.