



Unicorn - Malignant haemangioendothelioma of nose & paranasal sinuses

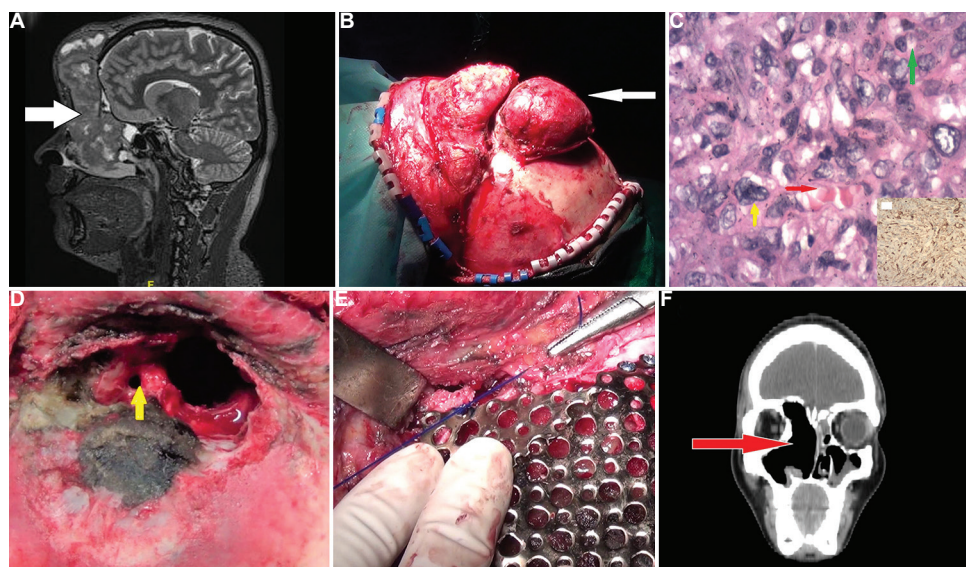


Figure. (A) Magnetic resonance imaging showing a heterogeneous mass in the right nasal cavity, maxillary sinus and orbit with frontal bone erosion (white arrow). (B) A flap elevated from the underlying forehead swelling (white arrow). (C) Photomicrograph showing sheets of round-to-oval tumour cells with eosinophilic cytoplasm and intracytoplasmic vacuoles (green arrow), Red blood cells within the vascular lumina (red arrow), mild-to-moderate nuclear atypia (yellow arrow) (H and E, $\times 40$) Inset showing positive immunohistochemistry with CD31 positivity in tumour cells ($\times 20$). (D) Post-tumour resection showing roof of the orbit and supraorbital cell (yellow arrow). (E) Titanium plate reconstruction post-tumour excision. (F) Post-operative computed tomography image showing no residual tumour.

Video available at ijmr.org.in.

A 21 yr old male[†] presented to the ENT department, Jawaharlal Institute of Postgraduate Medical Education & Research, Puducherry, India, in October 2016, with recurrent swelling in the inner aspect of the right eye along with watering and a forehead swelling for six months. Previous excision of a similar mass was alone in April 2014. Examination showed a well-defined swelling of 4×3 cm in the right medial canthus and a midline forehead swelling of 16×15 cm starting from the root of the nose.

Fine-needle aspiration cytology showed malignant haemangioendothelioma. Imaging showed a mass in the right nose, maxillary sinus and ethmoidal sinus extending into the right orbit with frontal bone erosion and minimal intracranial extension (Figure A). Craniofacial resection and external fronto-ethmoidectomy (Figure B and F, Video) was done along with radiotherapy in view of mitotic figures (Figure C), nuclear pleomorphism and CD31 positivity (Figure D). He was followed up for three years with no recurrence as per imaging (Figure E).

[†]Patient's consent obtained to publish clinical information and images.

Epithelioid haemangioendothelioma (EHE) is a rare vascular tumour with an incidence of 1 in 1,000,000 cases. Its occurrence in paranasal sinuses is rare, and it poses a histologic enigma due to its similarity to other tumours.

Acknowledgment: Authors acknowledge Dr Arun Alexander for performing the surgery and providing the surgical images.

Conflicts of Interest: None.

**Subhashini Puducherry Ravichandran¹
& Pampa Ch Toi^{2,*}**

Departments of ¹ENT & ²Pathology, Jawaharlal
Institute of Postgraduate Medical Education &
Research, Puducherry 605 006, India

**For correspondence:*
pampa.toi@gmail.com

Received November 20, 2019